

Anaplastic Large Cell Lymphoma (ALCL) In Women with Breast Implants: Preliminary FDA Findings and Analyses

January 2011

Center for Devices and Radiological Health

U.S. Food and Drug Administration



Anaplastic Large Cell Lymphoma (ALCL) In Women with Breast Implants: Preliminary FDA Findings and Analyses

Table of Contents

Executive Summary	3
Purpose.....	5
Overview.....	5
Review of the Literature	6
Methods.....	6
Case Studies	6
Epidemiological Studies	9
Other Study Observations	10
Summary of Key Findings	11
Recommendations for Health Care Providers.....	12
FDA Activities	12
How to Report Information to the FDA.....	13
Sources	14
Glossary of Terms as Used in this Document.....	17
Appendix A: Literature Review Methods.....	18
Appendix B: Detailed Characteristics of Published Cases	20

Anaplastic Large Cell Lymphoma (ALCL) In Women with Breast Implants: Preliminary FDA Findings and Analyses

Executive Summary

Reports in the scientific community have suggested a possible association between anaplastic large cell lymphoma (ALCL) and breast implants. In this document we summarize the scientific data the FDA used to assess the possible association. It represents our current understanding, based on the published scientific literature on ALCL in women with breast implants and information gathered through the FDA's contact with other regulatory authorities, scientific experts, and breast implant manufacturers. The document includes the FDA's analyses of the data and steps we plan to take to better understand and characterize the possible association.

Although ALCL is extremely rare, the FDA believes that women with breast implants may have a very small but increased risk of developing this disease in the scar capsule adjacent to the implant. Based on available information, it is not possible to confirm with statistical certainty that breast implants cause ALCL. At this time, data appear to indicate that the incidence of ALCL is very low, even in breast implant patients. Currently it is not possible to identify a type of implant (silicone versus saline) or a reason for implant (reconstruction versus aesthetic augmentation) associated with a smaller or greater risk.

The FDA is interested in learning more about the actual incidence of ALCL in women with breast implants, the characteristics of breast implants that might increase the risk of ALCL, and the pathological characteristics and clinical features of ALCL in women with breast implants. To this end, FDA is collaborating with the American Society of Plastic Surgeons to establish a registry of cases of women with breast implants who have been diagnosed with ALCL.

Health care providers should be aware ALCL in women with breast implants is a very rare condition; when it occurs, it has been identified most frequently in patients undergoing implant revision operations for late onset, persistent seroma. The FDA does not recommend prophylactic breast implant removal in patients without symptoms or other abnormalities. Current recommendations are described below. As we learn more about ALCL in women with breast implants, these recommendations may change.

- Consider the possibility of ALCL when you have a patient with late onset, persistent peri-implant seroma. In some cases, patients presented with capsular contracture or masses adjacent to the breast implant. If you have a patient with suspected ALCL, refer her to an appropriate specialist for evaluation. When testing for ALCL, collect fresh seroma fluid and representative portions of the capsule and send for pathology tests to rule out ALCL. Diagnostic evaluation should include cytological evaluation of seroma fluid with Wright Giemsa stained smears and cell block immunohistochemistry testing for cluster of differentiation (CD) and Anaplastic Lymphoma Kinase (ALK) markers.

- [Report all confirmed cases of ALCL in women with breast implants to the FDA](#). In some cases, the FDA may contact you for additional information. The FDA will keep the reporter's and the patient's identity confidential.
- Develop an individualized treatment plan in coordination with the patient's multi-disciplinary care team. Because of the small number of cases worldwide and variety of available treatment options, there is no single defined consensus treatment regimen.

Some researchers have suggested that breast implant-associated ALCL may represent a new clinically entity with less-aggressive (indolent) behavior ([Li, 2010](#); [Miranda et al, 2009](#); [Thompson et al, 2010](#)). Because of the small number of cases and the short median duration of follow-up, the FDA believes it is premature to draw conclusions regarding the prognosis of ALCL in women with breast implants.

Because the risk of ALCL appears very small, FDA believes that the totality of evidence continues to support a reasonable assurance that FDA-approved breast implants are safe and effective when used as labeled.

Purpose

This document summarizes the scientific data that the Food and Drug Administration (FDA) used to assess the possible association between [breast implants and anaplastic large cell lymphoma](#) (ALCL). It represents our current understanding, based on the published scientific literature on ALCL in women with breast implants and information gathered through the FDA's contact with other regulatory authorities, scientific experts, and breast implant manufacturers. The document includes the FDA's analyses of the data and steps the FDA plans to take to better understand and characterize the possible association. Although ALCL is extremely rare, the FDA believes that women with breast implants may have a very small but increased risk of developing this disease.

Overview

Anaplastic large cell lymphoma (ALCL) is a rare type of non-Hodgkin lymphoma (NHL), a cancer involving the cells of the immune system. According to the [Surveillance, Epidemiology, and End Results \(SEER\) Program](#) of the National Cancer Institute, approximately 1 in 500,000 women is diagnosed with ALCL in the United States each year. ALCL in the breast is even more rare; approximately 3 in 100 million women per year in the United States are diagnosed with ALCL in the breast ([Altekruse et al., 2010](#)).

ALCL is characterized by abnormal growth of T-lymphocytes (T-cells) and strong expression of a protein, cytokine receptor CD30. ALCL can involve many parts of the body, including the lymph nodes and skin. There are currently two major variants of ALCL recognized in the literature, one of which expresses the protein anaplastic lymphoma kinase (ALK-positive) and a second which does not (ALK-negative).

Reports in the scientific community have suggested a possible association between ALK-negative ALCL and silicone and saline-filled breast implants. In a thorough review of scientific literature published from January 1997 through May 2010, the FDA identified 34 unique cases of ALCL in women with breast implants throughout the world. The FDA's adverse event reporting systems also contain 17 reports of ALCL in women with breast implants. Additional cases have been identified through the FDA's contact with other regulatory authorities, scientific experts, and breast implant manufacturers. In total, the FDA is aware of approximately 60 case reports of ALCL in women with breast implants worldwide. The exact number is difficult to verify because reports from regulatory agencies and scientific experts often duplicate those found in the scientific literature.

According to the American Society of Plastic Surgeons, nearly four million breast implant procedures were performed in the United States from 1998 – 2009. The total number of implants worldwide is estimated to be between 5-10 million.

Although the total number of ALCL cases in women with breast implants is extremely low, it is higher than would be expected from the [SEER data](#) alone. Furthermore, these cases seem to follow fairly consistent patterns, including the close proximity of the ALCL to the breast

implants and the type of tumor pathology. Because of this, the FDA believes that women with breast implants may have a very small but increased risk of developing ALCL in the scar capsule adjacent to the implant. Because the risk of ALCL appears very small, FDA believes that the totality of evidence continues to support a reasonable assurance that FDA-approved breast implants are safe and effective when used as labeled.

Review of the Literature

Methods

The FDA's formal analysis of the published scientific literature involved searching PubMed, Embase, Web of Science, Cambridge Scientific Abstracts (CSA), EBSCO, and BIOSIS for published papers and abstracts about ALCL and breast implants. The search criteria were tailored to the indexing terms and search engines for the specific databases searched. Abstracts (or titles if an abstract was unavailable) of retrieved references were screened for relevance, and references cited in the resulting publications were evaluated to identify any additional ALCL case reports or epidemiologic studies.

The databases, search criteria and number of references retrieved are summarized in [Appendix A](#).

Case Studies

In the scientific literature from January 1, 1997 through May 21, 2010, the FDA identified a total of 18 published reports involving 37 patients with breast implants and ALCL. With the duplicates removed, the FDA analysis included 34 unique cases.

Of the 34 cases, the median time from breast implant placement to ALCL diagnosis was 8 years, with a range from 1 year to 23 years. Most patients were diagnosed when they sought medical treatment for implant-related symptoms such as persistent seromas, capsular contractures, or peri-implant masses warranting breast implant revision operations. In each case, lymphoma cells were found in the effusion fluid (seroma) surrounding the implant, in the fibrous capsule, or within a peri-implant mass. Typically, there was no invasion beyond the fibrous capsule into the breast parenchyma.

Figure 1 illustrates the location of the reports of ALCL adjacent to the breast implant.

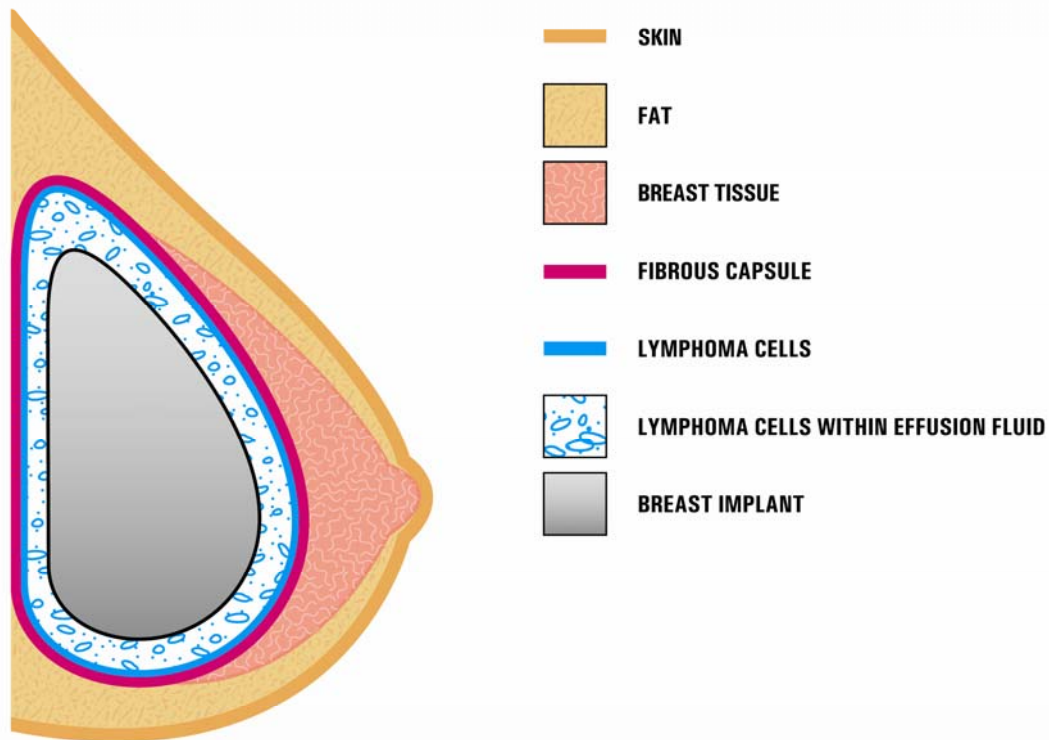


Figure 1. Presence of ALCL cells in close proximity to a breast implant. In most cases, the ALCL cells were found in the effusion fluid (seroma) surrounding the implant or contained within the fibrous capsule. ALCL is lymphoma, a type of cancer involving cells of the immune system. It is not cancer of the breast tissue, and typically, invasion of the lymphoma beyond the fibrous capsule into the breast parenchyma was not observed. Modified from [Thompson et al. \(2010\)](#).

ALCL has occurred in women who received implants for both reconstruction and aesthetic (sometimes also referred to as cosmetic) augmentation and in women with both silicone and saline-filled breast implants. Of the 34 cases, 11 patients received implants for breast reconstruction, 19 patients received implants for breast augmentation, and four patients had no reason for implant reported. Twenty-four patients had silicone-filled breast implants, seven had saline-filled breast implants, and three patients had no fill type reported. Only four cases included information about the texture of the breast implant surface; all four of these cases involved textured-surface implants. Based on this and the other available information, FDA believes that at this time, it is not possible to identify if a specific type of breast implant is uniquely associated with ALCL.

Summary characteristics of the 34 cases of breast implant associated ALCL are shown in table 1. Additional information for each individual case can be found in [Appendix B](#).

Table 1. Characteristics of 34 Unique Cases of ALCL in Women with Breast Implants

Age (years)	Median	51
	Range	28-87
	<i>No age specified</i>	8
Type of Implant	Silicone	24
	Saline	7
	<i>No implant type specified</i>	3
Texture of Implant	Textured	4
	Smooth	0
	<i>No surface texture specified</i>	30
Time from Implant to ALCL Diagnosis (years)	Median	8
	Range	1-23
	<i>No time to diagnosis specified</i>	11
Reason for Implant	Reconstruction	11
	Augmentation	19
	<i>No reason specified</i>	4

Consistent with an ALCL diagnosis, the CD30 status was positive in all 29 of the reports that included this information. However, unlike ALCL cases in the rest of the body that can be either ALK-positive or ALK-negative, the 26 reports of ALCL in women with breast implants that included ALK status were all ALK-negative.

Treatment was reported for 20 patients. Most had the implants removed, and some went on to receive treatment with radiation and/or chemotherapy. Overall, the outcomes appeared to be more favorable than would typically be expected for systemic ALCL. Outcomes were reported for 19 cases. Of these, 14 patients had no evidence of disease at last follow-up. However, most cases were diagnosed with early stage disease, and follow-up on many cases was limited. At present, it cannot be determined if these patients have a different prognosis than patients who present with ALCL at other sites unassociated with breast implants.

Epidemiological Studies

In the scientific literature from January 1, 1997 through May 21, 2010, the FDA identified three epidemiologic papers that discussed ALCL in women with breast implants. There were no prospective cohort studies that evaluate the association between breast implants and ALCL.

We identified one case-controlled study by [de Jong et al. \(2008\)](#). This paper suggested an association between breast implants and ALCL. However, the authors noted that “the absolute risk is exceedingly low due to the rare occurrence of ALCL of the breast.”

In this individually matched case-control study, de Jong and colleagues searched a population-based nationwide pathology database in the Netherlands for all patients with lymphoma in the breast diagnosed between 1990 and 2006. Cases were defined as women with a histologically confirmed diagnosis of primary ALCL in the breast. Controls, identified from the same database and selected for each case, consisted of 3 to 7 women who had histologically confirmed diagnoses of primary lymphoma in the breast other than ALCL. Cases were matched for age at diagnosis (+/- 5 years) and year of diagnosis (+/- 2 years). Pathology reports were reviewed for all controls, and questionnaires were sent to the treating physicians of all cases and controls to collect information on medical history (including previous malignancies, staging results, presence of breast prostheses and mammography results).

A total of 11 women with ALCL were selected as cases in the study, five of whom had breast implants. An additional 47 women with lymphomas of the breast other than ALCL were selected as controls.

Using sophisticated statistical methodology (conditional logistic regression analysis), the authors estimated the odds ratio of ALCL associated with breast implants to be 18.2 (95% CI 2.1-156.8). In other words, the odds of having a breast implant were 18.2 times higher in ALCL patients than in the control lymphoma patients.

While the study concluded that the probability of developing ALCL was greater in women with breast implants compared to those without, uncertainties regarding the initial case classifications impact the interpretation of the findings. For example, in this study three patients (one with breast implants and two control cases) had bilateral breast involvement at the time of this study, and the two controls experienced distant nodal involvement. Therefore it is not clear whether these controls were indeed primary breast lymphomas. Furthermore, one of the 5 ALCL patients with breast implants in this investigation developed ALCL within a year after implantation – a timeframe considered by some to be too short to cause the development of ALCL.

[Brinton \(2007\)](#) studied the relationship of silicone breast implants to cancer at other sites and observed that the majority of cases of lymphoma in patients with breast implants have emerged either in the breast, in the periprosthetic capsule, or in proximity to the implant. The report pointed out that in the general population, breast lymphomas are a rare disease entity and that most are of B-cell origin. In contrast, nearly every case of lymphoma among breast implant patients has been of T-cell phenotype and ALCL in particular.

Brinton also noted several methodological issues that limit the ability to interpret the clinical data and large scale epidemiologic studies of breast implants and cancer. The paper explains that the small number of patients in cancer studies has limited the ability to study rare diseases, such as ALCL and lymphomas in general, as well as the ability to conduct subgroup analyses to adequately evaluate the effect of different characteristics of breast implants such as surface texture and surgical technique. In the paper, Brinton also identifies other methodological issues including short follow-up times, the inability to adjust for potential confounders when comparing cancer rates in epidemiologic studies with the general population, and the types of controls selected in cohort studies for comparison to women with breast implants.

[Lipworth, Tarone, and McLaughlin \(2009\)](#) reviewed five long-term follow up studies of women with aesthetic breast implants. Their analyses included over 43,000 women. In this review, the authors reported 48 observed incident cases of Non-Hodgkin's Lymphoma compared with 53.9 cases expected, resulting in a standardized incidence ratio (SIR) of 0.89. They observed no cases of primary breast lymphomas. Although this analysis indicates a lower risk of lymphoma in women with breast implants, it has two weaknesses that make it less informative for estimating the likelihood of a relationship between ALCL and breast implants. First, all the studies reviewed in this paper began following patients more than 30 years ago (from 1953 to 1974), but ALCL was not identified in the literature until 1985 ([Stein et al](#)). Second, the number of women studied and their duration of follow-up were not sufficient to exclude a very rare relationship between breast implants and ALCL.

Other Study Observations

Some researchers have suggested that ALK-negative, breast implant-associated ALCL may represent a new clinically entity with non-aggressive (indolent) behavior ([Li, 2010](#); [Miranda, 2009](#), [Thompson et al, 2010](#)). In the scientific literature, 19 reports of ALCL cases in women with breast implants included information on ALCL recurrence or the development of systemic lymphoma. Of these, 14 patients remained free of disease during the follow-up period ([Rodén, 2008](#)). Only 14 of the 34 cases in the literature reported the duration of follow-up. In these patients, the average follow-up was about 12 months, with a range from 1 month to 108 months. Furthermore, outcomes for these patients may have been reported to be less aggressive than for other ALCL cases because most of the patients were diagnosed with early stage ALCL. Because of the small number of cases and the short median duration of follow-up, the FDA believes it is premature to draw conclusions regarding the prognosis of ALCL in women with breast implants.

Summary of Key Findings

1. There is a possible association between breast implants and ALCL.

Based on the published case studies and epidemiological research, the FDA believes that there is a possible association between breast implants and ALCL. Based on available data, the incidence of ALCL, even in breast implant patients, appears to be very low.

However, despite the low total number of reported cases, certain factors suggest the occurrence of ALCL in patients with breast implants may not be coincidence. If ALCL in women with breast implants were due only to chance, one would expect for it to occur with similar frequency in all parts of the breast. Instead, ALCL is usually located in the region immediately surrounding the breast implant. Furthermore, the vast majority of primary breast lymphomas reported in patients without breast implants are of the B-cell phenotype ([Domchek, 2002](#)). In contrast, ALCL is a T-cell lymphoma, suggesting the observation may be more than chance ([Miranda, 2009](#)).

2. At this time, it is not possible to identify a specific type of implant associated with a lower or higher risk of ALCL.

We do not have enough information to determine if a specific type of implant (silicone versus saline) or reason for implant (reconstruction versus aesthetic augmentation) is associated with a smaller or greater risk. [Brody et al. \(2010\)](#) noted that to date, when the implant type has been identified, ALCL has been found more frequently in association with breast implants having a *textured* outer shell rather than a *smooth* outer shell. However, most of the ALCL cases reported in breast implant patients failed to include information about the texture of the shell. Therefore the FDA cannot determine whether ALCL may be found more or less frequently in women with textured breast implants than in women with smooth breast implants.

3. There is uncertainty about the true cause of ALCL in women with breast implants.

Based on available information, it is not possible to confirm with statistical certainty that breast implants cause ALCL. Because ALCL is so rare, even in breast implant patients, a definitive study would need to collect data on hundreds of thousands of women for more than 10 years. Even then, causality may not be conclusively established.

FDA is interested in learning more about the actual incidence of ALCL in women with breast implants, the characteristics of breast implants that might increase the risk of ALCL, and the pathological characteristics and clinical features of ALCL in women with breast implants.

To gather additional information about ALCL in women with breast implants, FDA is establishing [a registry](#) in collaboration with the American Society of Plastic Surgeons and other experts in the clinical and scientific communities.

Recommendations for Health Care Providers

Health care providers should be aware that ALCL has been found in the peri-implant area of some women with breast implants.

ALCL is a very rare condition; when it occurs, it has been most often identified in patients undergoing implant revision operations for late onset, persistent seroma. Because it is so rare and most often identified in patients with late onset of symptoms such as pain, lumps, swelling, or asymmetry, it is unlikely that increased screening of asymptomatic patients would change their clinical outcomes. The FDA does not recommend prophylactic breast implant removal in patients without symptoms or other abnormality.

Current recommendations are described below. As the FDA learns more about ALCL in patients with breast implants, these recommendations may change.

- Consider the possibility of ALCL when you have a patient with late onset, persistent peri-implant seroma. In some cases, patients presented with capsular contracture or masses adjacent to the breast implant. If you have a patient with suspected ALCL, refer her to an appropriate specialist for evaluation. When testing for ALCL, collect fresh seroma fluid and representative portions of the capsule and send for pathology tests to rule out ALCL. Diagnostic evaluation should include cytological evaluation of seroma fluid with Wright Giemsa stained smears and cell block immunohistochemistry testing for cluster of differentiation (CD) and Anaplastic Lymphoma Kinase (ALK) markers.
- [Report all confirmed cases of ALCL in women with breast implants to the FDA](#). In some cases, the FDA may contact you for additional information. The FDA will keep the reporter's and the patient's identity confidential.
- Develop an individualized treatment plan in coordination with the patient's multi-disciplinary care team. Because of the small number of cases worldwide, there is no defined consensus treatment regimen.

FDA Activities

The FDA recently published a [safety communication](#) to inform health care providers and the public about a possible association between breast implants and ALCL.

The FDA continues to evaluate available information to understand the nature and possible factors contributing to ALCL in women with breast implants. As part of this evaluation, FDA searched its adverse event reporting systems for reports received between January 1, 1995 and December 1, 2010, including information submitted by manufacturers as part of their required post-approval studies. This search identified 17 reports of possible ALCL in women with breast implants. The significance of these reports is difficult to establish because relevant information

is often absent or unconfirmed, including clinical and pathology findings, breast implant type and duration, and location of possible ALCL in the body. The FDA is following up on these reports to obtain further information from the manufacturers. At present, the FDA has determined that at least six of these reports are duplicates of the cases described in the “Review of Literature” section above, and two of the reports have been determined to be non-ALCL lymphomas.

In order to gather additional information to better characterize ALCL in women with breast implants, the American Society of Plastic Surgeons (ASPS) and other experts in the clinical and scientific communities have agreed to pursue a collaboration with FDA to develop a registry of women with breast implants and ALCL. While the details of the collaboration are being developed, the FDA is advising health care providers to evaluate breast implant patients with suspected ALCL according to the recommendations above and to [report findings on confirmed ALCL cases to the FDA](#). The FDA has also reminded breast implant manufacturers of their requirement to report confirmed cases. The FDA will update the public as new information is obtained and evaluated.

In an effort to ensure that patients receiving breast implants are informed of the possible link between ALCL and breast implants, the FDA will be working with breast implant manufacturers in the coming months to update their product labeling materials for patients and providers.

How to Report Information to the FDA

If you are a health care provider and you have identified ALCL in breast implant patients, please file a voluntary report through MedWatch, the FDA’s Safety Information and Adverse Event Reporting Program online at <https://www.accessdata.fda.gov/scripts/medwatch/medwatch-online.htm> or at 1-800-332-1088.

To help us learn as much as possible about ALCL in women with breast implants, please specify:

- The term “ALCL Case Report” in section B5 (*Describe Event, Problem or Product Use Error*) of the MedWatch form
- Patient age, gender, race/ethnicity
- ALCL diagnosis: date of diagnosis, anatomic site of ALCL, whether ALCL was primary in this site and pathologically confirmed
- Clinical presentation
- Detailed pathology findings
- Breast implant exposure: date implanted, brand and type of implant (saline or silicone-filled), type of implant surface (smooth or textured), complications, length of time from implant insertion, and history of subsequent revision surgeries
- Treatment(s) the patient received
- Name, contact information and medical specialty of reporter

All reports to the FDA are strictly confidential and protect individual patient privacy.

Sources

1. Alobeid B, Sevilla DW, El-Tamer MB, Murty VV, Savage DG, Bhagat G. Aggressive presentation of breast implant-associated ALK-1 negative anaplastic large cell lymphoma with bilateral axillary lymph node involvement. *Leuk Lymphoma*. 2009 May;50(5):831-3.
2. Altekruse SF, Kosary CL, Krapcho M, Neyman N, Aminou R, Waldron W, Ruhl J, Howlander N, Tatalovich Z, Cho H, Mariotto A, Eisner MP, Lewis DR, Cronin K, Chen HS, Feuer EJ, Stinchcomb DG, Edwards BK (eds). SEER Cancer Statistics Review, 1975-2007, National Cancer Institute. Bethesda, MD, http://seer.cancer.gov/csr/1975_2007/, Table 19.28 , based on November 2009 SEER data submission, posted to the SEER web site, 2010.
3. Bishara MR, Ross C, Sur M. Primary anaplastic large cell lymphoma of the breast arising in reconstruction mammoplasty capsule of saline filled breast implant after radical mastectomy for breast cancer: an unusual case presentation. *Diagn Pathol*. 2009 Apr 2;4:11.
4. Brinton LA. The relationship of silicone breast implants and cancer at other sites. *Plast Reconstr Surg*. 2007 Dec;120(7 Suppl 1):94S-102S.
5. Brody GS, Deapen D, Gill P, Epstein A, Martin S, Elatra W. T cell non-Hodgkin's anaplastic lymphoma associated with one style of breast implants. San Antonio, Texas: American Society of Plastic Surgeons Annual Conference, March 20-23, 2010. Scientific Session IX: Breast B, Oral communication and abstract 42.
6. de Jong D, Vasmel WL, de Boer JP, Verhave G, Barbé E, Casparie MK, van Leeuwen FE. Anaplastic large-cell lymphoma in women with breast implants. *JAMA*. 2008 Nov 5;300(17):2030-5.
7. De Peralta-Venturina M, Miranda RN, Medeiros LJ, Gualco G, Bacchi CE, Amin M. Anaplastic large cell lymphoma arising in association with breast implants and mimicking recurrent breast carcinoma: A report of five cases. *Lab.Invest*. 2009;89:153 (37A).
8. Domchek SM, Hecht JL, Fleming MD, Pinkus GS, Canellos GP. Lymphomas of the breast: primary and secondary involvement. *Cancer*. 2002 Jan 1;94(1):6-13.
9. Evens A, Chiu B. The challenges of epidemiologic research in non-hodgkin Lymphoma. *JAMA*. 2008;300(17):2059-2061.

10. Farkash EA, Ferry JA, Harris NL, Hochberg EP, Takvorian RW, Zuckerman DS, Sohani AR. Rare lymphoid malignancies of the breast: a report of two cases illustrating potential diagnostic pitfalls. *J Hematop.* 2009 Aug 20;2(4):237-44.
11. Fritzsche FR, Pahl S, Petersen I, Burkhardt M, Dankof A, Dietel M, Kristiansen G. Anaplastic large-cell non-Hodgkin's lymphoma of the breast in periprosthetic localisation 32 years after treatment for primary breast cancer--a case report. *Virchows Arch.* 2006 Nov;449(5):561-4.
12. Ganjoo K, Advani R, Mariappan MR, McMillan A, Horning S. Non-Hodgkin lymphoma of the breast. *Cancer.* 2007 Jul 1;110(1):25-30.
13. Gaudet G, Friedberg JW, Weng A, Pinkus GS, Freedman AS. Breast lymphoma associated with breast implants: two case-reports and a review of the literature. *Leuk Lymphoma.* 2002 Jan;43(1):115-9.
14. Gualco G, Bacchi CE. B-cell and T-cell lymphomas of the breast: clinical--pathological features of 53 cases. *Int J Surg Pathol.* 2008 Oct;16(4):407-13.
15. Gualco G, Chioato L, Harrington WJ Jr, Weiss LM, Bacchi CE. Primary and secondary T-cell lymphomas of the breast: clinico-pathologic features of 11 cases. *Appl Immunohistochem Mol Morphol.* 2009 Jul;17(4):301-6.
16. Jaffe ES. Anaplastic large cell lymphoma: the shifting sands of diagnostic hematopathology. *Mod Pathol.* 2001 Mar;14(3):219-28.
17. Jeanneret-Sozzi W, Taghian A, Epelbaum R, Poortmans P, Zwahlen D, Amsler B, Villette S, Belkacémi Y, Nguyen T, Scalliet P, Maingon P, Gutiérrez C, Gastelblum P, Krengli M, Raad RA, Ozsahin M, Mirimanoff RO. Primary breast lymphoma: patient profile, outcome and prognostic factors. A multicentre Rare Cancer Network study. *BMC Cancer.* 2008 Apr 1;8:86.
18. Keech JA Jr, Creech BJ. Anaplastic T-cell lymphoma in proximity to a saline-filled breast implant. *Plast Reconstr Surg.* 1997 Aug;100(2):554-5.
19. Li S, Lee AK. *Int J Clin Exp Pathol.* 2009 Oct 15;3(1):117-27.
20. Lipworth L, Tarone RE, McLaughlin JK. Breast implants and lymphoma risk: a review of the epidemiologic evidence through 2008. *Plast Reconstr Surg.* 2009 Mar;123(3):790-3.
21. Medeiros LJ, Elenitoba-Johnson KS. Anaplastic large cell lymphoma. *Am J Clin Pathol.* 2007 May;127(5):707-22.
22. Miranda RN, Lin L, Talwalkar SS, Manning JT, Medeiros LJ. Anaplastic large cell lymphoma involving the breast: a clinicopathologic study of 6 cases and review of the literature. *Arch Pathol Lab Med.* 2009 Sep;133(9):1383-90.

23. Mora P, Melo AC, Amorim GLS, Scheliga AA. Primary T-cell Anaplastic Lymphoma Associated to a Breast Implant: Case Report. *Haematologica* 2009;94:658-9 (1723).
24. Newman MK, Zimmel NJ, Bandak AZ, Kaplan BJ. Primary breast lymphoma in a patient with silicone breast implants: a case report and review of the literature. *J Plast Reconstr Aesthet Surg*. 2008 Jul;61(7):822-5.
25. Olack B, Gupta R, Brooks GS. Anaplastic large cell lymphoma arising in a saline breast implant capsule after tissue expander breast reconstruction. *Ann Plast Surg*. 2007 Jul;59(1):56-7.
26. Popplewell L, Chang K, Olevsky O, Nademanee A, Forman S. Primary anaplastic large cell lymphoma of the breast occurring in patients with silicone breast implants. *Blood* 2004;104(11):4563.
27. Roden AC, Macon WR, Keeney GL, Myers JL, Feldman AL, Dogan A. Seroma-associated primary anaplastic large-cell lymphoma adjacent to breast implants: an indolent T-cell lymphoproliferative disorder. *Mod Pathol*. 2008 Apr;21(4):455-63.
28. Sahoo S, Rosen PP, Feddersen RM, Viswanatha DS, Clark DA, Chadburn A. Anaplastic large cell lymphoma arising in a silicone breast implant capsule: a case report and review of the literature. *Arch Pathol Lab Med*. 2003 Mar;127(3):e115-8.
29. Savage KJ, Harris NL, Vose JM, Ullrich F, Jaffe ES, Connors JM, Rimsza L, Pileri SA, Chhanabhai M, Gascoyne RD, Armitage JO, Weisenburger DD; International Peripheral T-Cell Lymphoma Project. ALK- anaplastic large-cell lymphoma is clinically and immunophenotypically different from both ALK+ ALCL and peripheral T-cell lymphoma, not otherwise specified: report from the International Peripheral T-Cell Lymphoma Project. *Blood*. 2008 Jun 15;111(12):5496-504.
30. Stein H, Mason DY, Gerdes J, O'Connor N, Wainscoat J, Pallesen G, Gatter K, Falini B, Delsol G, Lemke H, et al. The expression of the Hodgkin's disease associated antigen Ki-1 in reactive and neoplastic lymphoid tissue: evidence that Reed-Sternberg cells and histiocytic malignancies are derived from activated lymphoid cells. *Blood* 1985 Oct;66:848-858.
31. Thompson PA, Lade S, Webster H, Ryan G, Prince HM. Effusion-associated anaplastic large cell lymphoma of the breast: time for it to be defined as a distinct clinico-pathological entity. *Haematologica*. 2010 Nov;95(11):1977-9.
32. Wong AK, Lopategui J, Clancy S, Kulber D, Bose S. Anaplastic large cell lymphoma associated with a breast implant capsule: a case report and review of the literature. *Am J Surg Pathol*. 2008 Aug;32(8):1265-8.

Glossary of Terms as Used in this Document

Absolute Risk: The chance that a particular event will occur within a specified population.

ALCL: Anaplastic Large Cell Lymphoma, a rare type of T-cell non-Hodgkin lymphoma.

Anaplastic Lymphoma Kinase (ALK): A protein marker that is present in some ALCLs.

Capsular Contracture: A tightening of the fibrous capsule surrounding a breast implant, one of the most common complications of breast implant surgery.

CD30: A cell membrane protein that is associated with ALCL. The cluster of differentiation (CD) is a way to identify molecules present on the surface of white blood cells.

Effusion Fluid: Fluid surrounding a breast implant, contained within the fibrous capsule. Also referred to as seroma.

Fibrous Capsule: The scar tissue that the body forms around a breast implant or other type of implant in the body.

Lymphoma The general term for a group of cancers that originates in the lymphatic system.

Parenchyma: Breast tissue.

Peri-Implant Mass: A dense growth in the area near a breast implant.

Prophylactic: A preventative measure, something undertaken in order to reduce risk.

Relative Risk: The ratio of the chance of a disease developing among members of a population that are exposed to some factor compared to a group that has not been exposed to the factor.

SEER Program (Surveillance, Epidemiology, and End Results Program): National Cancer Institute's collection of cancer statistics.

Seroma: Fluid surrounding a breast implant, contained within the fibrous capsule. Also referred to as effusion fluid.

T-lymphocyte (T-cell): A type of white blood cell (lymphocyte) that develops in the thymus.

Appendix A

Literature Review Methods

The initial screening identified 55 unique citations or abstracts published between 1995 and May 21, 2010. Full articles were obtained for the relevant papers. Review of these papers identified 18 published case reports of patients with breast implants who were diagnosed with ALCL, one epidemiologic study of ALCL, one review of the epidemiologic literature, one editorial about the epidemiologic studies of ALCL, and a number other references that either duplicated reports of ALCL cases or were not specific to ALCL. Duplicate reports and references not specific to ALCL were removed. Finally, references cited in the resulting publications were evaluated to identify any additional ALCL case reports or epidemiologic studies. None were identified. The table below gives the details of the databases, search terms, and resulting references in the literature review.

Literature Review Methods		
Database Name	Search Criteria	Number of References Retrieved
PubMed (Variations on the term “implant” were used in order to include all relevant papers.)	breast AND (implant OR implants OR implant* OR implantation OR prosthesis OR prosthes* OR endoprothes*) AND lymphoma* --- did not limit at all to publication years or language	75
Embase (Embase thesaurus terms were used in this search)	'breast endoprosthesis'/exp AND ('large cell lymphoma'/exp OR 'lymphoma'/exp)	33
Web of Science	breast AND (implant* OR prosthes* OR endoprothes*) AND lymphoma* Years searched: 1899 to present for Science Citation Index, 1898 to present for Social Science Citation Index database	94

Literature Review Methods (continued)		
Database Name	Search Criteria	Number of References Retrieved
Cambridge Scientific Abstracts (CSA) Databases (Natural Science collection excluding MEDLINE databases as used in Pubmed above)	breast AND lymphoma* AND (Implant* OR prothes* OR endoprothes*)	36
Databases in EBSCOhost search: Academic Search Complete 1887 to present; CINAHL (Cumulative Index to Nursing and Allied Health Literature)- 1981 to present; International Pharmaceutical Abstracts - 1970 to present; Science and Technology Collection - 1900 to present	breast AND lymphoma* AND (implant* OR prothes* OR endoprothes*)	27
BIOSIS 2007 to present	breast AND (implant* OR prothes* OR endoprothes*) AND lymphoma*	16

Appendix B

Detailed Characteristics of 34 Published Cases of ALCL in Women with Breast Implants

(data not available for cells that are empty)

	Case	Reason for Implant	Age	Implant to ALCL Diagnosis (years)	Presentation (breast)	Capsule Involved	ALK-1
Li, 2010	1	R	58	5.5	seroma	+	-
Sahoo, 2003	2	A	33	14	seroma	+	-
Alobeid, 2009	3	R	68	16	peri-implant mass	+	-
Gualco, 2009	4	A	28	6	mastitis	+	-
Miranda, 2009	5	R	63	8	seroma		-
	6	A	40	9	peri-implant mass		-
	7		65		seroma	+	-
deJong, 2008	8	A	53	1		+	-
	9	A	49	23		+	-
	10	A	43	13		+	-
	11	A	29	3		+	-
	12	A	38	13		+	-
Bishara, 2009	13	R	66	7	capsular contraction	+	-
Keech, 1997	14	A	41	5	mass (non-specified)	+	
Fritzsche, 2006	15	R	72	16	skin ulceration		-
Gaudet, 2002	16	R	87	8	seroma	+	-
	17	R	50	9	subcutaneous nodules		-
Newman, 2008	18	A	52	14	seroma, mass (non-specified)	+	
Olack, 2007	19	R	56	7	seroma	+	-

	Case	Reason for Implant	Age	Implant to ALCL Diagnosis (years)	Presentation (breast)	Capsule Involved	ALK-1
Roden, 2008	20	R	45	7	seroma		-
	21	R	59	3	seroma	+	-
	22	A	34	4	seroma	+	-
	23	A	44		seroma		-
Wong, 2008	24	A	40	19	capsular contraction	+	-
Farkash, 2009	25	R	54	17	seroma	+	-
*Poppewell, 2004	26	A			mass (non-specified)		
	27	A			mass (non-specified)		
	28	A			mass (non-specified)		
	29	A			mass (non-specified)		
	30	A			mass (non-specified)		
	31	A			seroma		
*De Peralta, 2009 **	32					+	-
	33					+	-
*Mora, 2009	34		56		peri-implant mass		-

*denotes abstract only; R=reconstruction; A=aesthetic augmentation (cosmetic);

**Three of the cases reported by De Peralta (2009) appeared to be duplicates to two cases reported by Miranda (2009) and one by Gualco (2009).